

Use of Cortisone in the Upper limb

Dr. Gavin Nimon

MBBS FRACS (ORTH) FRCS (Ed)

General Orthopaedic Surgeon
Upper Limb, Hand & Knee Injuries

Gavin Anthony Nimon

University of Adelaide- intern 1990 bst 91-93

Edinburgh/ Newcastle –Orthopaedic Registrar 1994

Advanced Trainee –Orthopaedics 1995-1998

Senior Registrar Year 1999 QEH

Senior Registrar/ Consultant PMR Edinburgh

Consultant DGRI 2000-2005

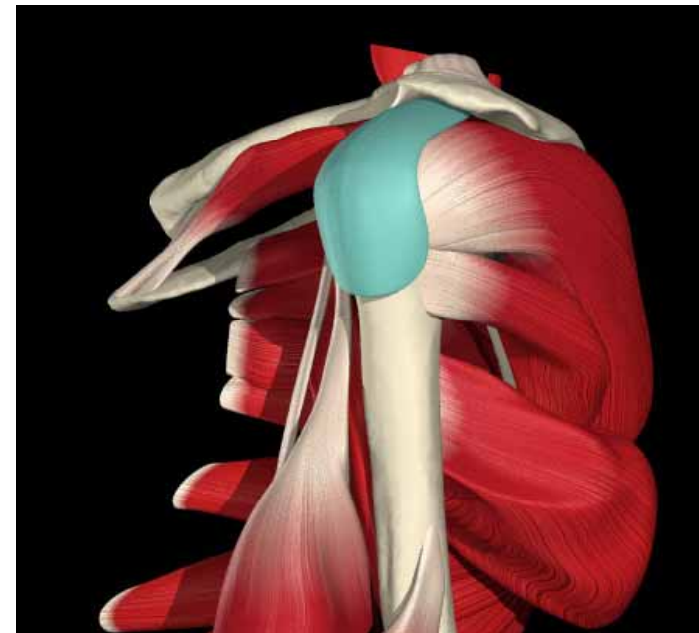
Senior Visiting Medical Specialist- QEH

Medical officer Glenelg Football Club



Rotator Cuff Spectrum

- Bursitis
- Tendinopathy
 - Cuff
 - Biceps
- Tear
- Arthropathy



Cause: -

- Factors
 - 1) Abnormality in Acromion
 - Developmental
 - Type III acromion (Bigliani)
 - 2) Primary degeneration of Rotator Cuff
- Note there is a familial incidence
- Relation to smoking
- Relation to Age and issue of asymptomatic (coping)

Assessment: -

History: -

- Age
- Site of pain
- Occurrence
- Past history (same shoulder or other)

Examination: -

- Tenderness
- Range of motion
- Arc of motion
- Crepitus
- Specific tests

Investigations: -

- X-rays (Ap and lateral scapular)
- Exclude oa (see state of ac joint and G-H subluxation)
- Ultrasound- confirm impingement
- MRI- more accurate for above and cuff tear
- [Injection as diagnostic](#)

Treatment

- Rest, NSAID's
- Physiotherapy- always
- Steroid Injections- try at least 1
- Surgical decompression
- Arthroscopic has replaced open as surgical Tx of choice

Cuff tear does not mean surgery
but

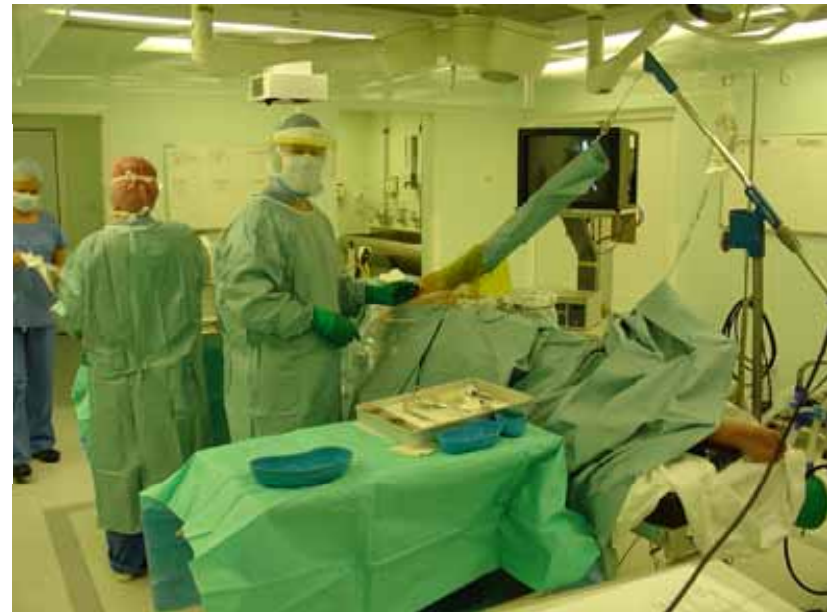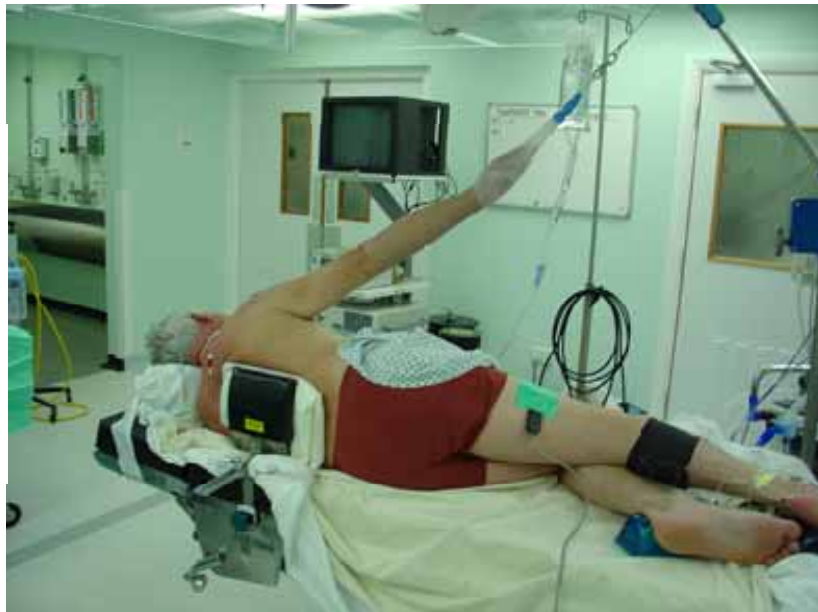If no better, failure of conservative
management doe not mean nothing!!

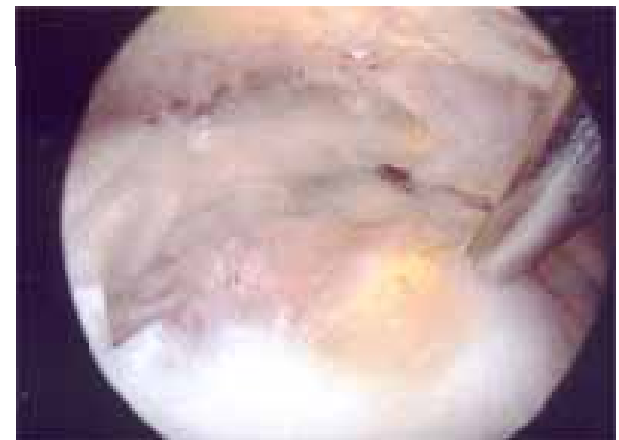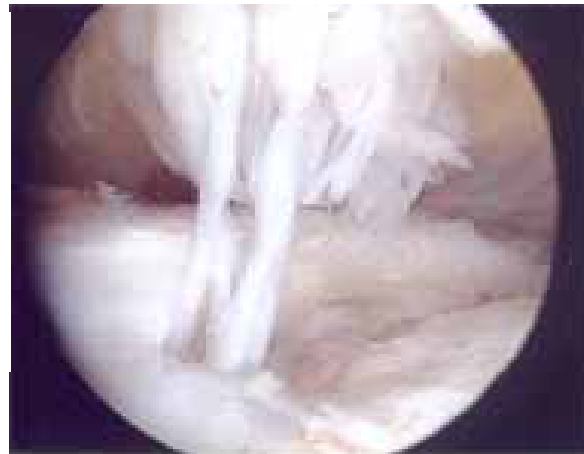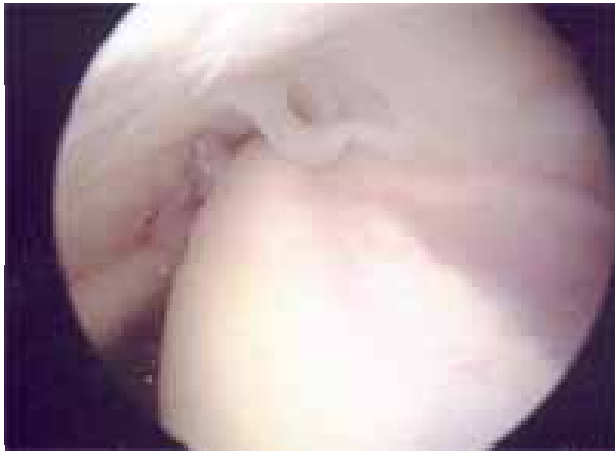Cuff Tear: -

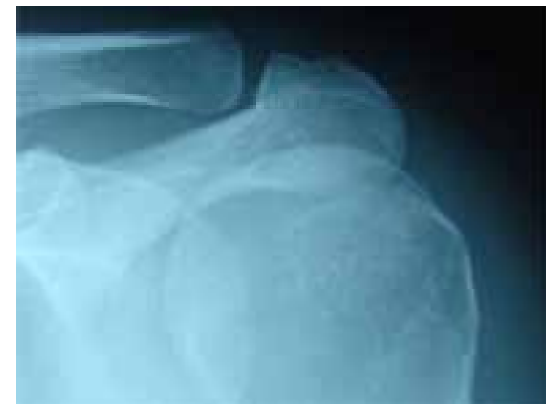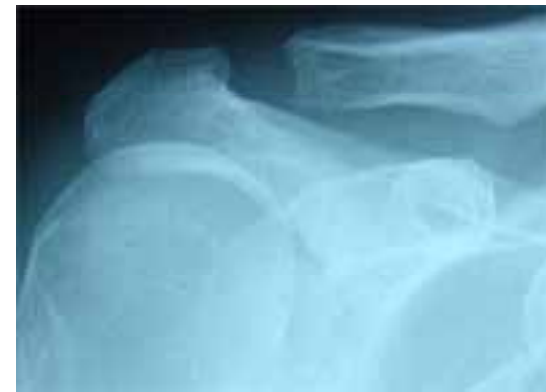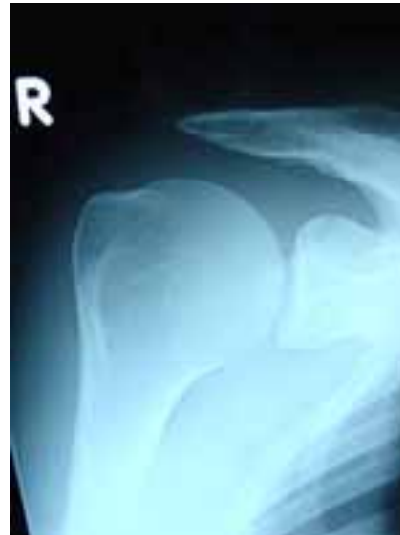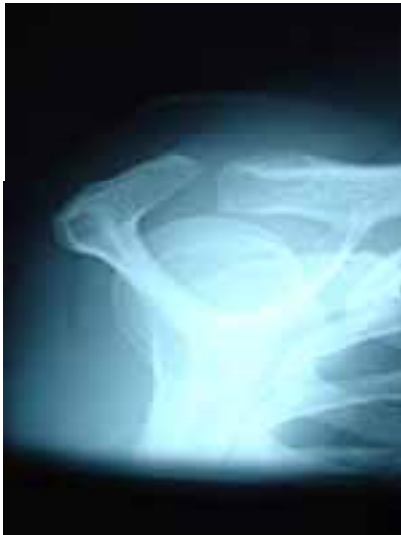- Issues
- Imaging not accurate often over calls (u/s > MRI)
 - High Incidence of asymptomatic cuff tears-
 - fall- sore shoulder u/s shows tear
 - Steroid injection- local- see if with analgesia arm moves ok
 - steroid allows it to settle
 - If becomes asymptomatic with 1 injection- restores prior

state

- If local or steroid do nothing after 1 month and physio? acute
- Repaired tear worthwhile if symptoms warrant, but if asymptomatic- repairing not worth it as could re tear







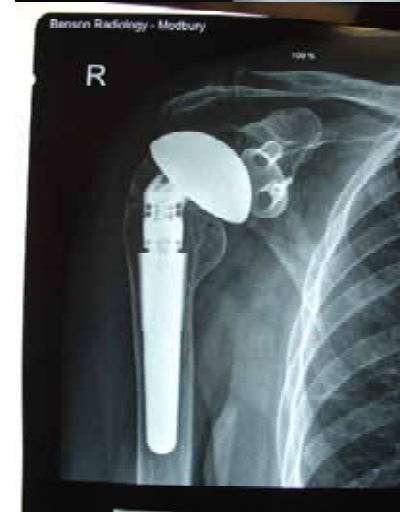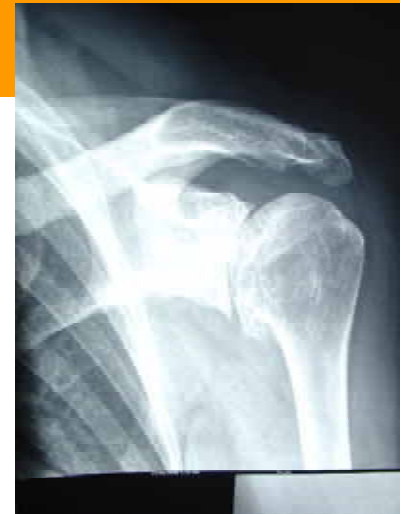Osteo arthritis

Options: -

NSAIDS's, physio, acupuncture
analgesia

Cortisone injection

TSR

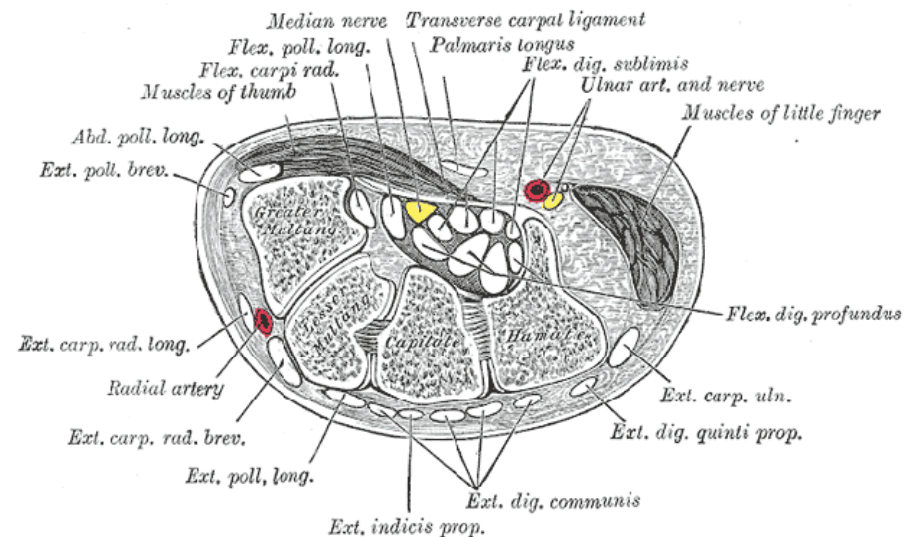


Hand and Elbow conditions- worth cortsione

- Neurological
 - Carpal Tunnel
- Degenerative
 - CMC arthritis
 - Ganglions
 - Trigger Fingers
 - Tennis Elbow
- Inflammatory
 - DeQuervain's tenosynovitis

Carpal Tunnel Syndrome

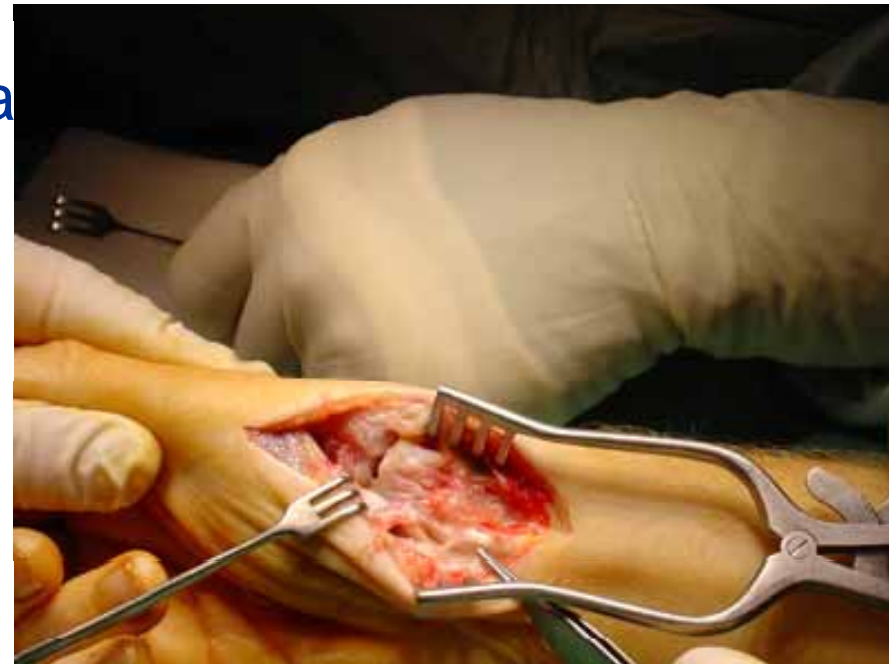- Common condition
- can offer cortisone (u/s guidance)
- however open release under LA
(cheap , safe and effective)



CMC Osteoarthritis

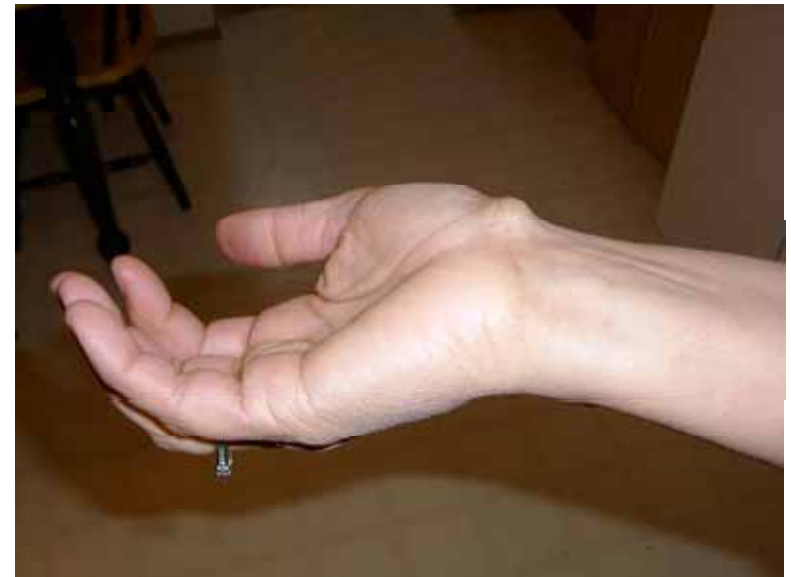- Very common
- Degenerative (female > male)
- Grind test +ve

- Tx
 - Splint/ physiotherapy
 - Steroid Injection
 - Trapezelectomy +/- suspensoplasty vs fusion
 - K wire and plaster 4-6 weeks



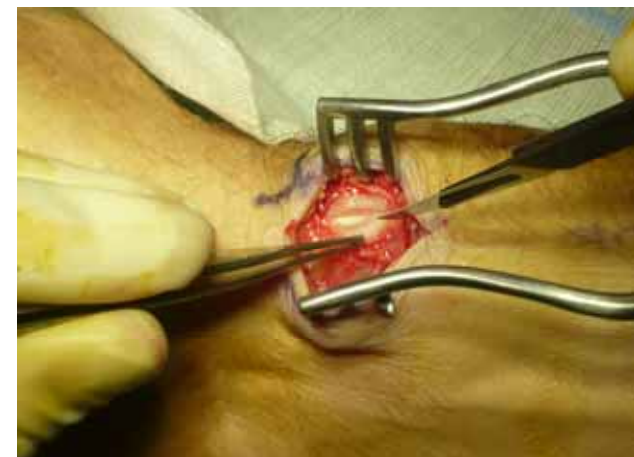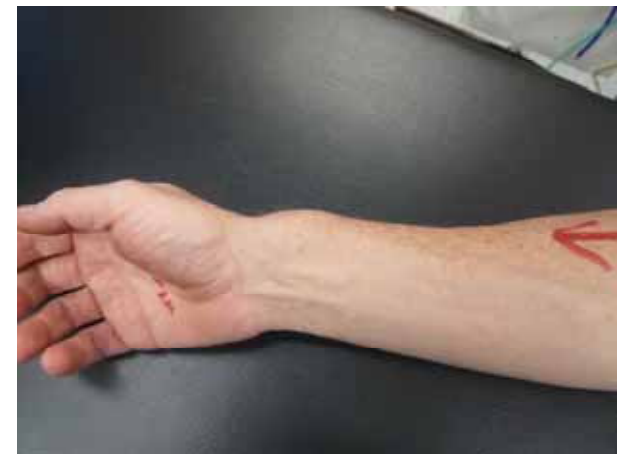Ganglions

- Surprisingly annoying to patient
- ? Degenerative or developmental
 - Remember steroid injection (& aspiration)
 - Surgery often under local useful
not 100% successful



Dequervain's Tenosynovitis

- 1st Extensor Compartment
- Finkelstein's test
- Physio
- Brace
- Inject
- Release under LA,
 - cheap, safe & effective



If not sure
Just like
“who wants to be a millionaire”

Phone a friend

04379 18552

Gavin Nimon- GP advice line