

Shoulder Surgery

Dr. Gavin Nimon

MBBS FRACS (ORTH) FRCS (Ed)

General Orthopaedic Surgeon
Shoulder, Hand & Knee Injuries

Gavin Anthony Nimon

University of Adelaide- intern 1990 bst 91-93

Edinburgh/ Newcastle –Orthopaedic Registrar 1994

Advanced Trainee –Orthopaedics 1995-1998

Senior Registrar Year 1999 QEH

Senior Registrar/ Consultant PMR Edinburgh

Consultant DGRI 2000-2005

Senior Visiting Medical Specialist- QEH

Medical officer Glenelg Football Club



Causes of Shoulder Symptoms

Neck

Referred pain from neck (usually posterior)

General

Brachial Neuritis

Polymyalgia Rheumatica

Inflammatory Arthropathy

Shoulder

Frozen Shoulder (Adhesive Capsulitis)

Rotator Cuff spectrum

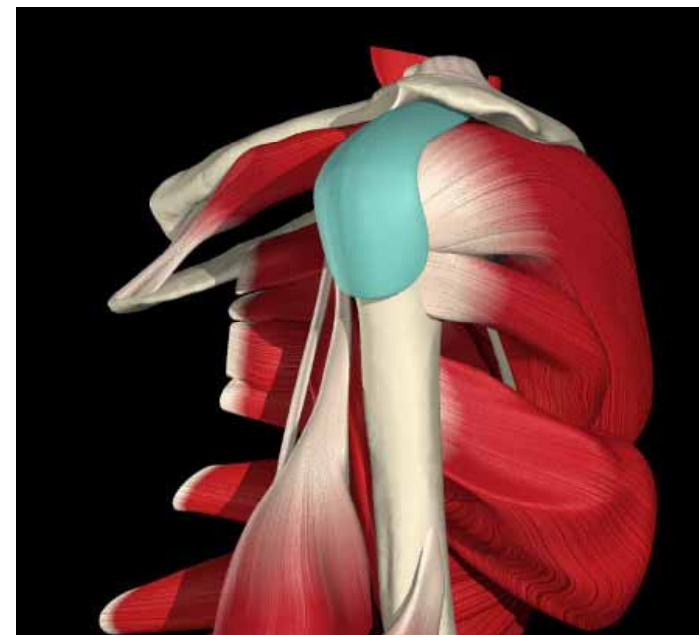
Degenerative arthritis

Instability

AC joint

Rotator Cuff Spectrum

- Bursitis
- Tendinopathy
 - Cuff
 - Biceps
- Tear
- Arthropathy



+/- ac joint oa or biceps

Cause: -

- Factors
 - 1) Abnormality in Acromion
 - Developmental
 - Type III acromion (Bigliani)
 - 2) Primary degeneration of Rotator Cuff
- Note there is a familial incidence
- Relation to smoking
- Relation to Age and issue of asymptomatic (coping)

Assessment: -

History: -

- Age
- Site of pain
- Occurrence
- Past history (same shoulder or other)

Examination: -

- Tenderness
- Range of motion
- Arc of motion
- Crepitus
- Specific tests

Investigations: -

- X-rays (Ap and lateral scapular)
- Exclude oa (see state of ac joint and G-H subluxation)
- Ultrasound- confirm impingement
- MRI- more accurate for above and cuff tear
- [Injection as diagnostic](#)

Treatment

- Rest, NSAID's
- Physiotherapy- always
- Steroid Injections- try at least 1
- Surgical decompression
- Arthroscopic has replaced open as surgical Tx of choice

Cuff tear does not mean surgery
but

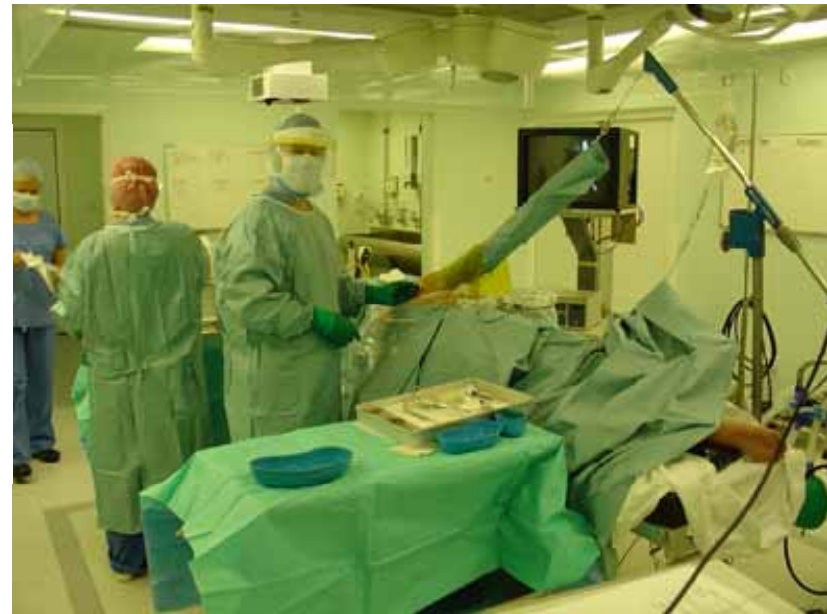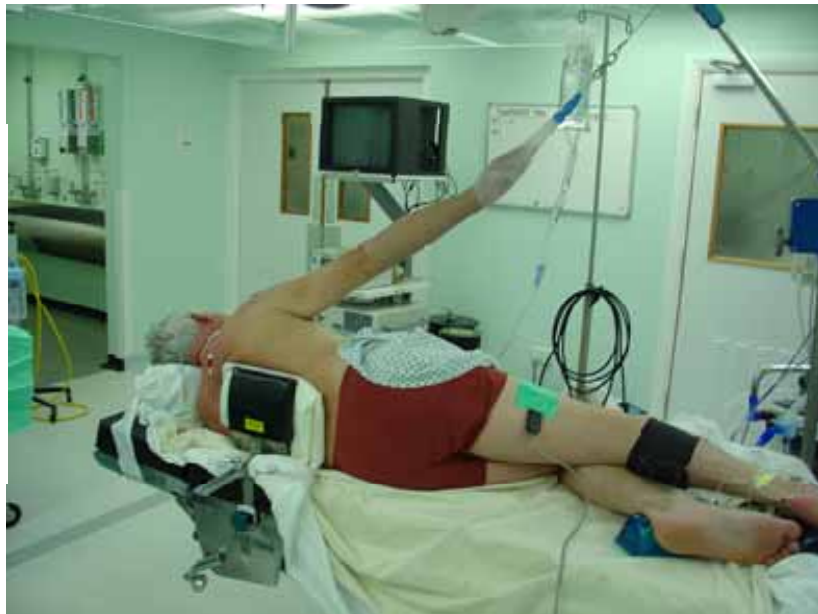If no better, failure of conservative
management doe not mean nothing!!

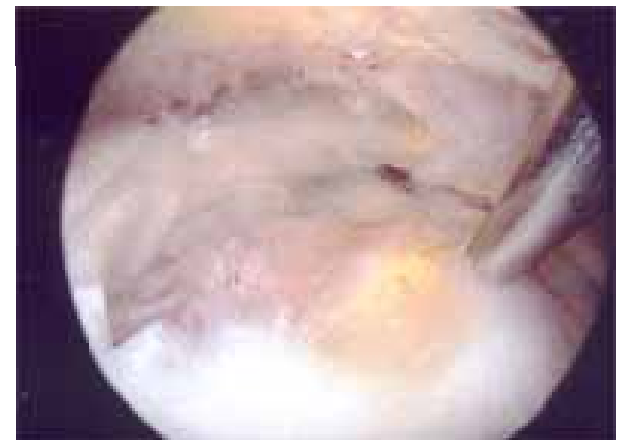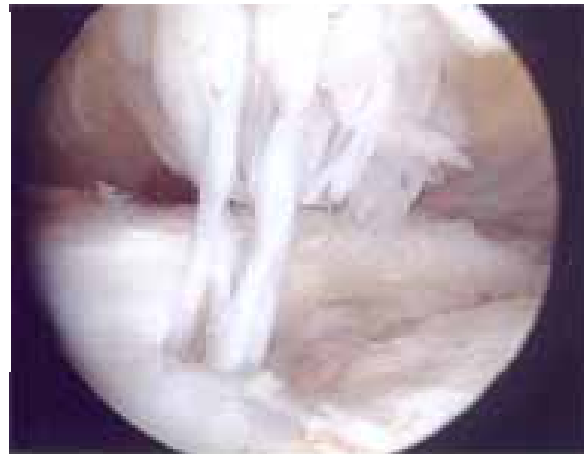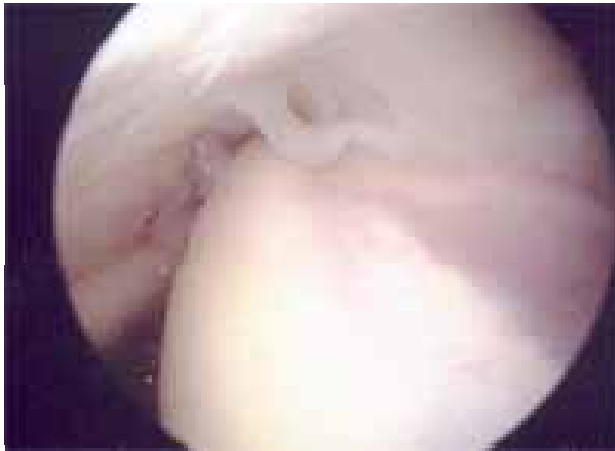Cuff Tear: -

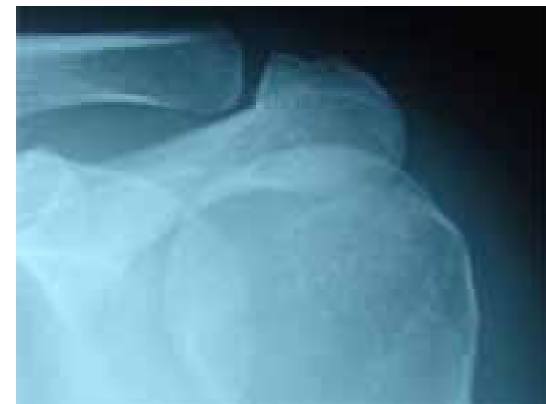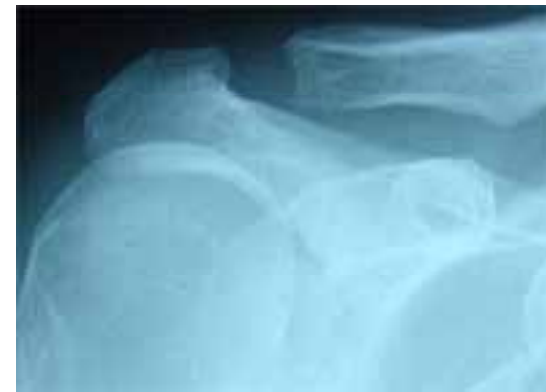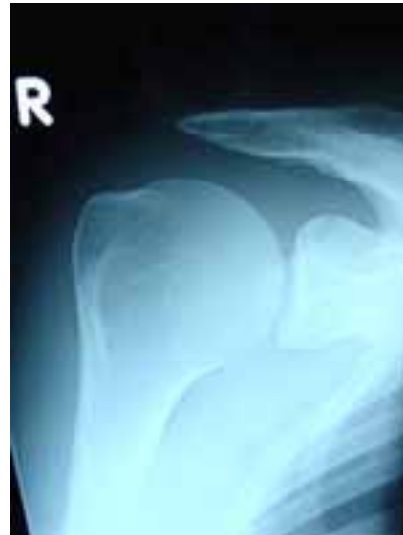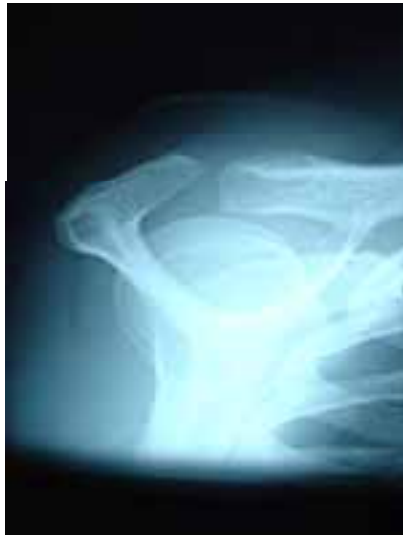- Issues
- Imaging not accurate often over calls (u/s > MRI)
 - High Incidence of asymptomatic cuff tears-
 - fall- sore shoulder u/s shows tear
 - Steroid injection- local- see if with analgesia arm moves ok
 - steroid allows it to settle
 - If becomes asymptomatic with 1 injection- restores prior

state

- If local or steroid do nothing after 1 month and physio? acute
- Repaired tear worthwhile if symptoms warrant, but if asymptomatic- repairing not worth it as could re tear







Videos

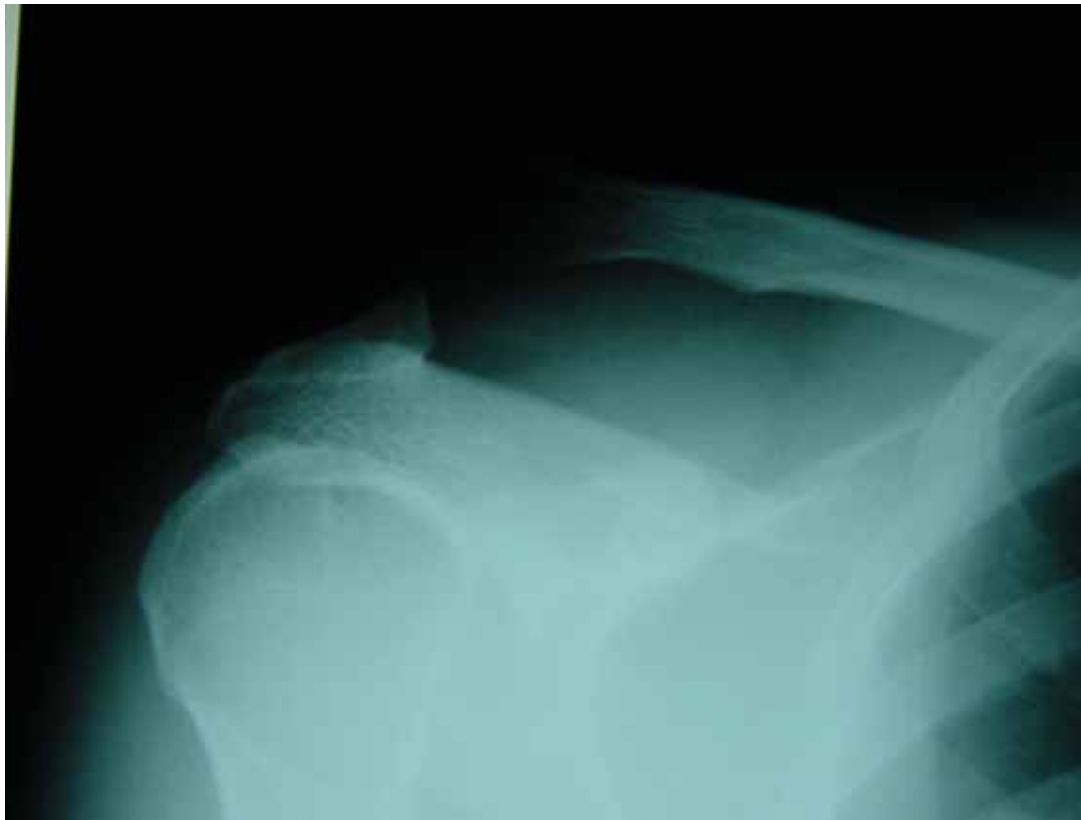- 1) arthroscopic decompression
- 2) arthroscopic cuff repair

GLENELG
ORTHOPAEDICS

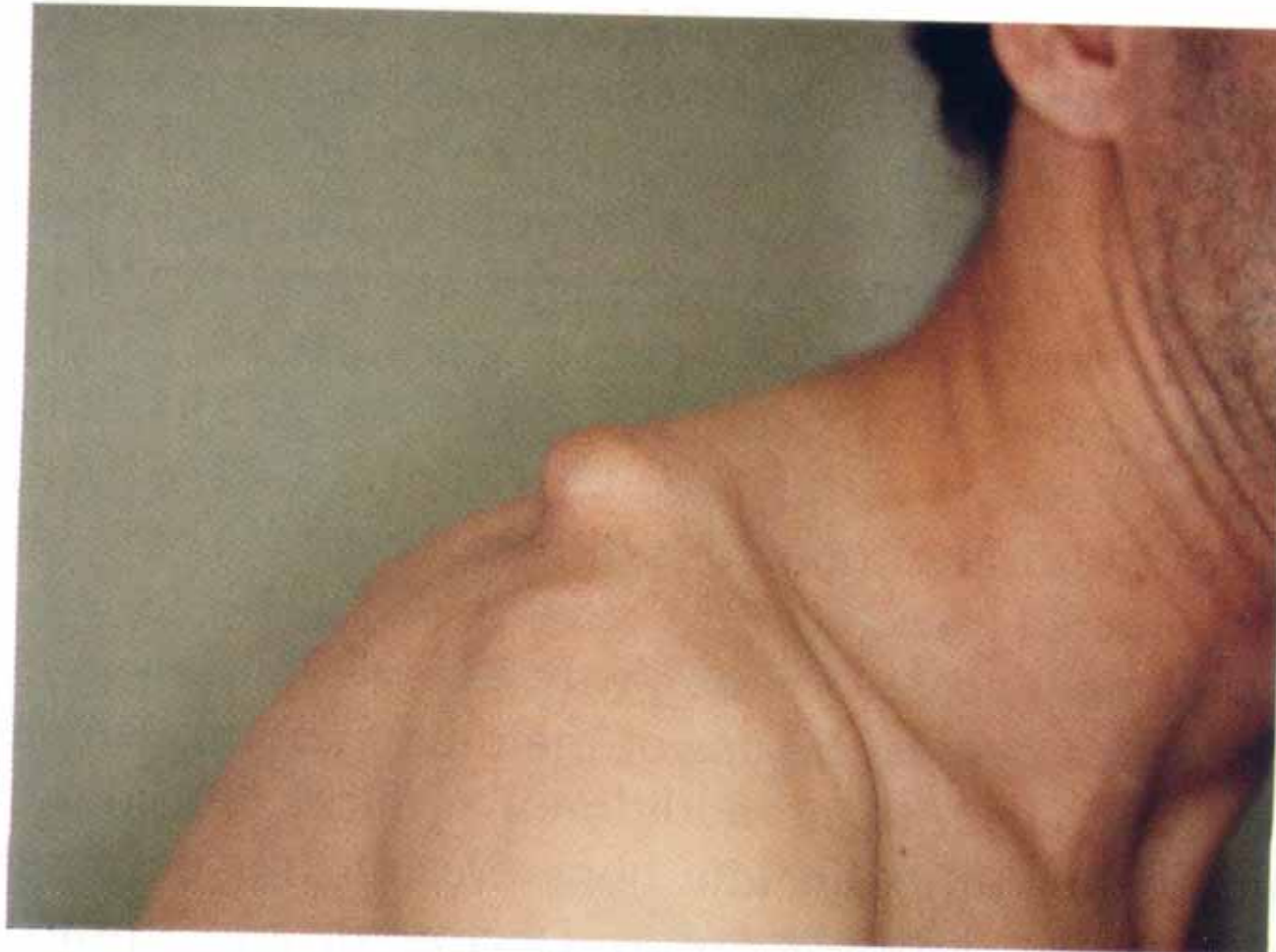


www.glen-orth.com

A-C Joint injury



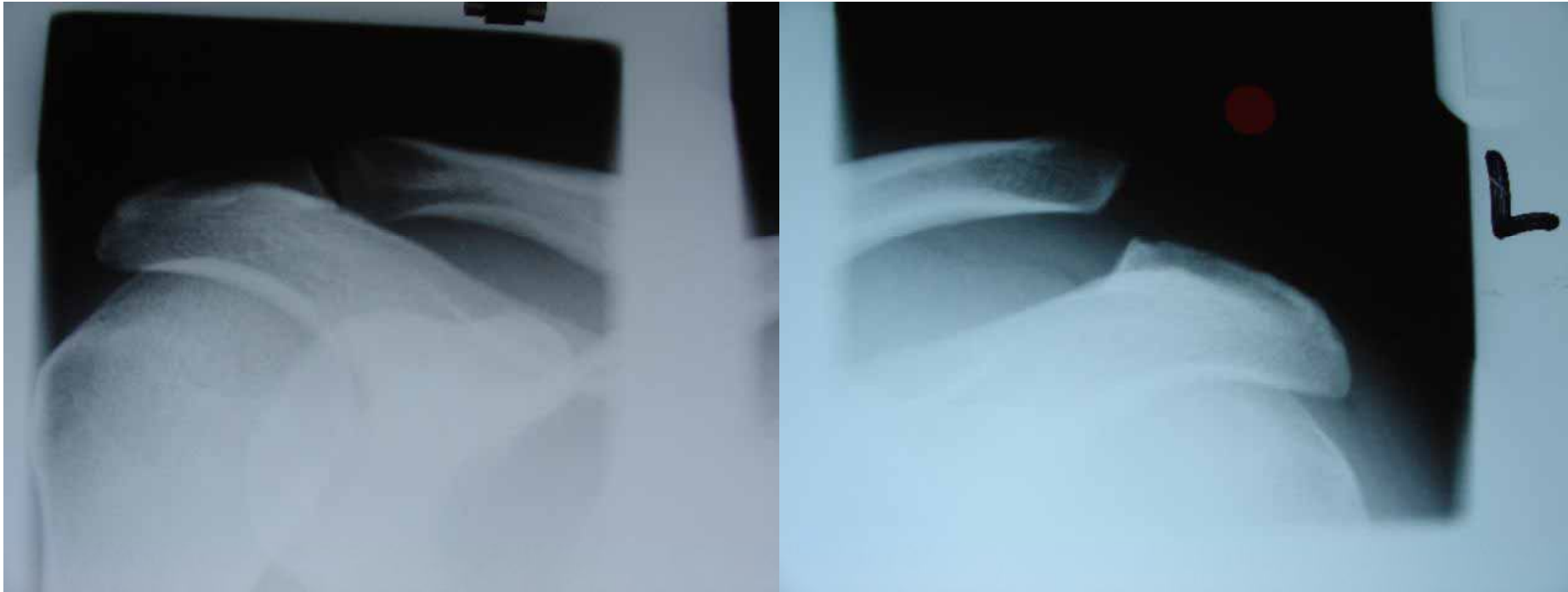
Fall on tip of shoulder or force transmitted through arm (straight)

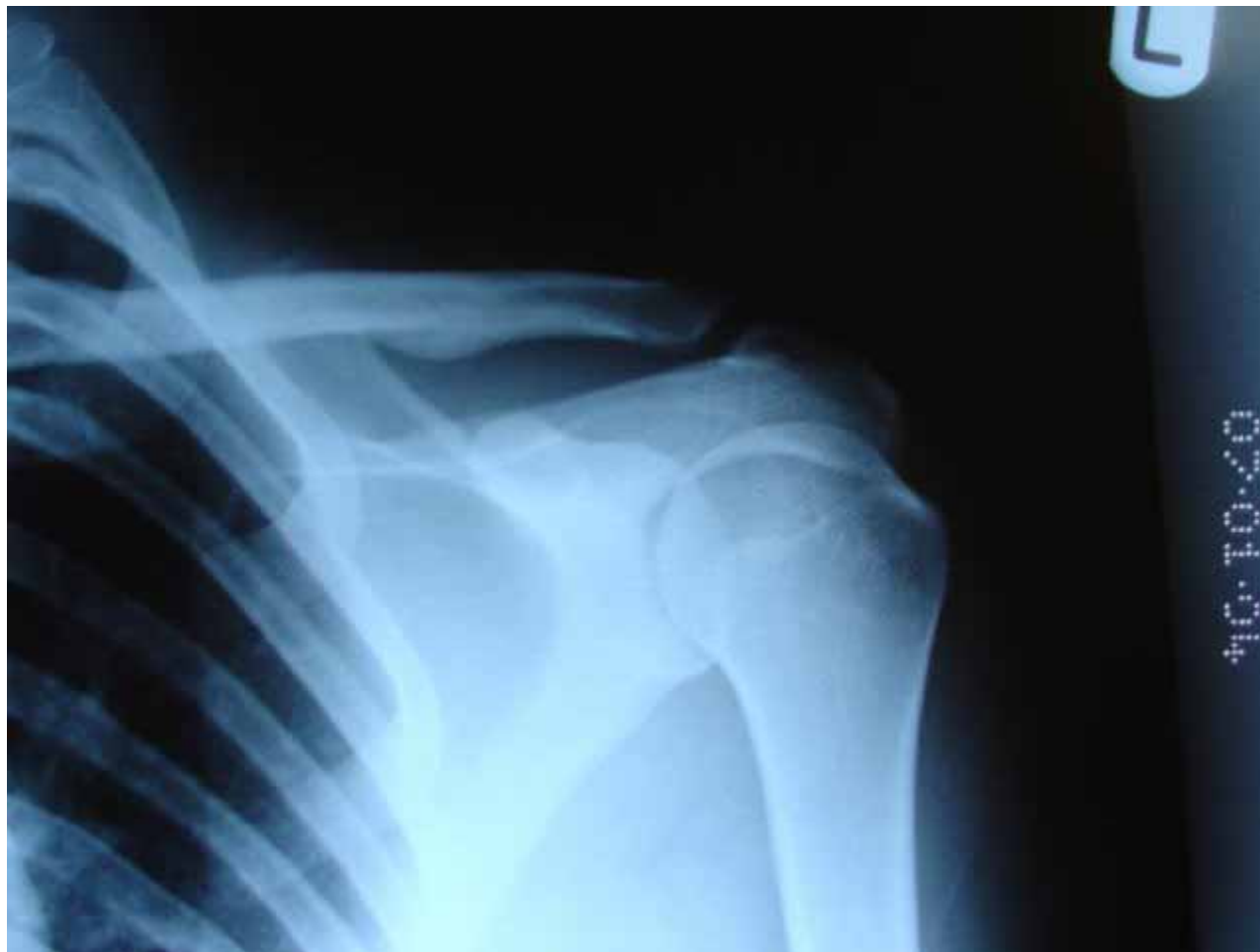

A



Upper Limb- AC Joint





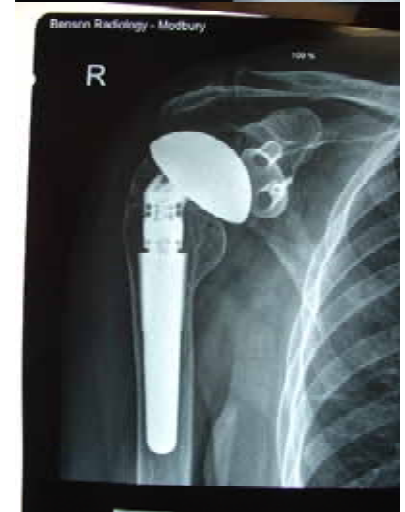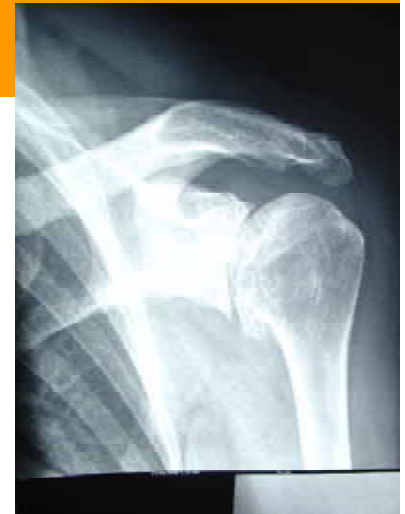Osteo arthritis

Options: -

NSAIDS's, physio, acupuncture
analgesia

Cortisone injection

TSR



If not sure
Just like
“who wants to be a millionaire”

Phone a friend

04379 18552

Gavin Nimon- GP advice line